INI- CET Nov 2020 Recall Questions

ENT

Q1 Arrange the components of the auditory pathway in their correct sequence?

1. Cochlear Nucleus
2. Inferior Colliculi
3. Lateral lemniscus
4. Medial geniculate body
5. Superior Olivary nucleus

A. 1→2→3→4→5
B. 1 → 5→3→2→4
C. 1→3→2→4→5
D. 1→3→5→2→4

Q2 **Endoscopic view of the right nasal cavity is given below. Identify the marked structure?**

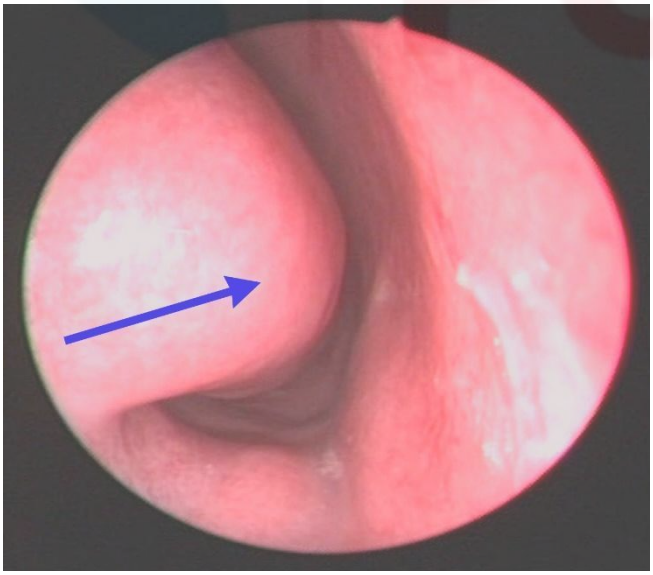

A. Inferior Turbinate
B. Middle turbinate

C. Superior Turbinate
D. Uncinate process

Q3 All of the following are seen in otitis media except

A. Bezold's abscess
B. Griesinger's sign
C. Battle sign
D. Delta sign

Q4 Which of the following are the objective tests of hearing?

1. BERA
2. OAE
3. PTA
4. Tympanometry

A. 1,2
B. 1,2 and 4
C. 2, 3 and 4
D. 1, 2, 3 and 4

Q5 Identify the view?

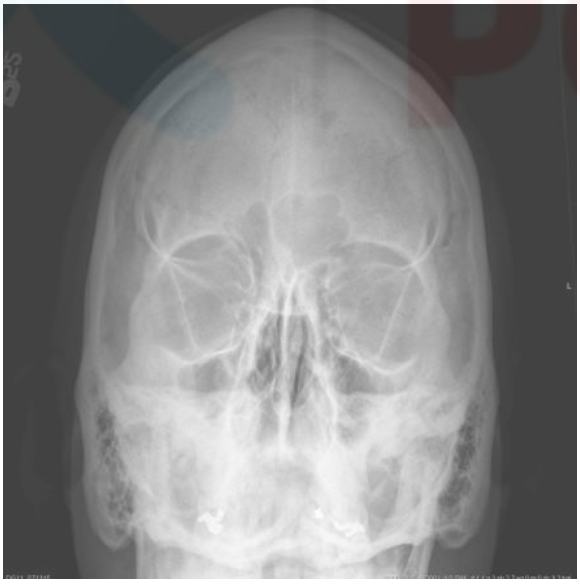

A. Water's view
B. Caldwell view
C. Sculler's view
D. Towne's view

ANSWERS

1.Answer: (B) 1→5→3→2→4

Explanation: Auditory pathway from the right cochlea -

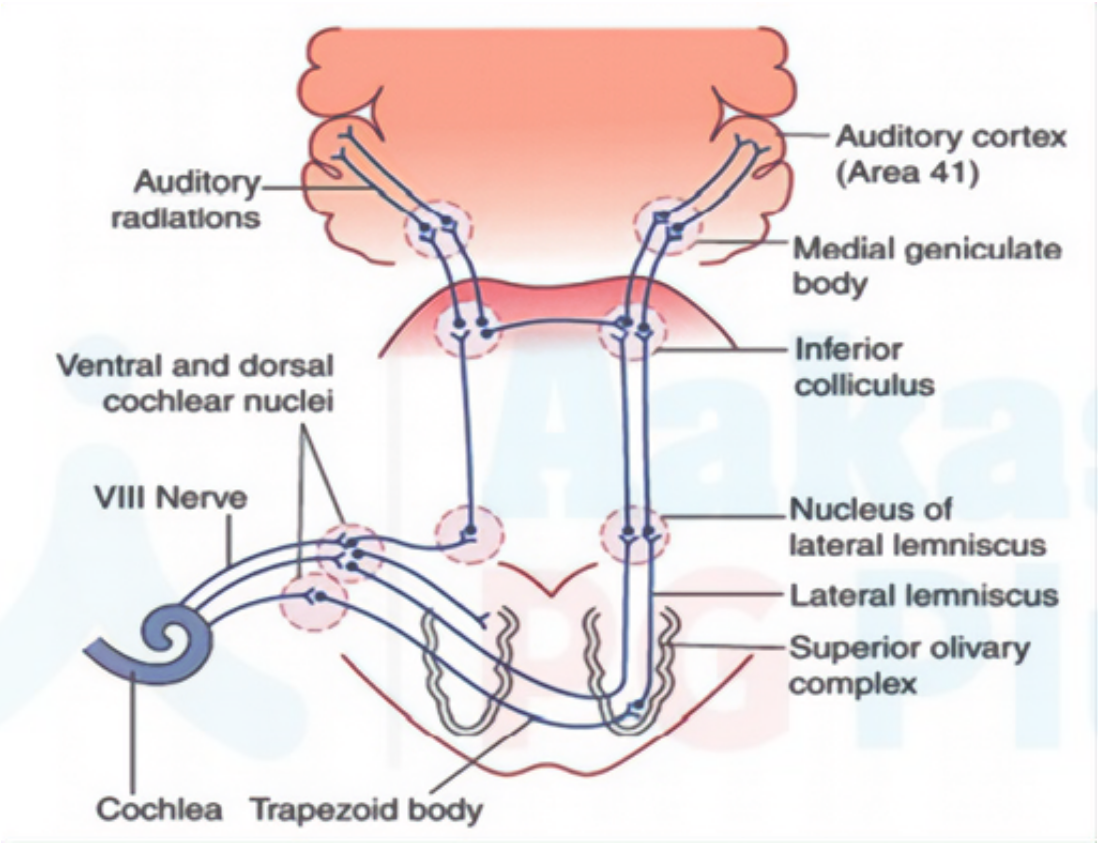

AUDITORY PATHWAY:

- **HAIR CELLS** are innervated by dendrites of **BIPOLAR CELLS** of **SPIRAL GANGLION** (situated in ROSENTHAL's CANAL)
- Axons of bipolar cells form the **cochlear division** of **CN VIII** and end in the dorsal and ventral COCHLEAR NUCLEI in the medulla.
- From cochlear nuclei, nuclei involved in sequence from below upwards are:

  1. Superior olivary complex

  2. Nucleus of lateral lemniscus

3. **Inferior colliculus**

4. **Medial geniculate body**

5. **Auditory cortex**

- The auditory fibres travel via the ipsilateral and contralateral routes to reach Broadmann's **Area 41- Superior Temporal Gyrus**
- Each ear is represented in both cerebral hemispheres.

Mnemonic –E. **COLI-MA: Eighth nerve, Cochlear nuclei, Superior Olivary complex, Lateral lemniscus, Inferior colliculus, Medial geniculate body and Auditory cortex.**

2.Answer: (A) Inferior Turbinate

Explanation: Area marked by the arrow is Inferior turbinate. Generally, only inferior turbinate & middle turbinate is visible on endoscopic examination

- Lateral wall of nose has bony projections known as **TURBINATES/Conchae** and the spaces below the Turbinates are called Meatuses

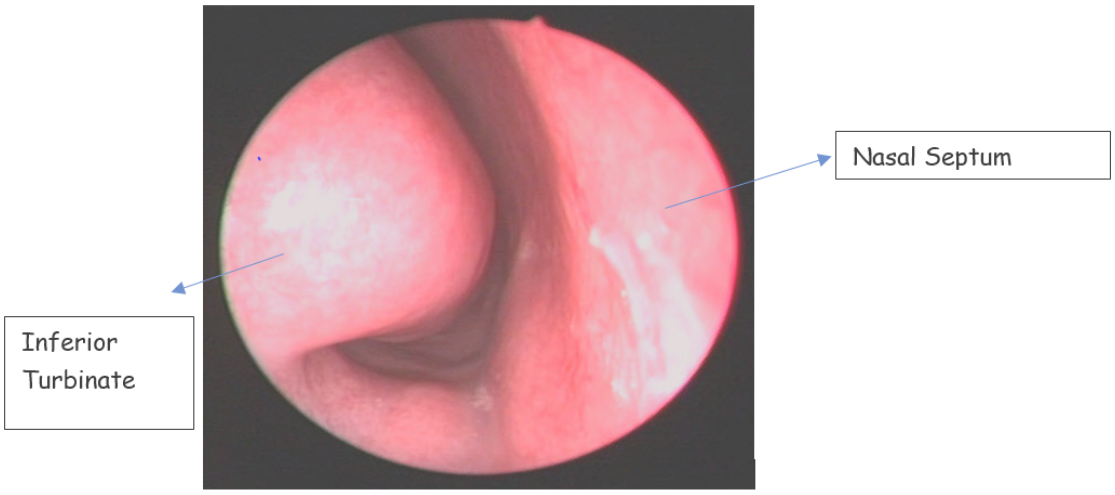

INFERIOR TURBINATE (Largest)	**Separate bone** Ethmoid Bone articulates with Inferior Turbinate
MIDDLE TURBINATE	Part of Ethmoid Bone
SUPERIOR TURBINATE	Part of Ethmoid Bone

- Inferior meatus has opening of Nasolacrimal duct
- CONCHA BULLOSA: Pneumatized turbinate (most commonly site: middle Turbinate)

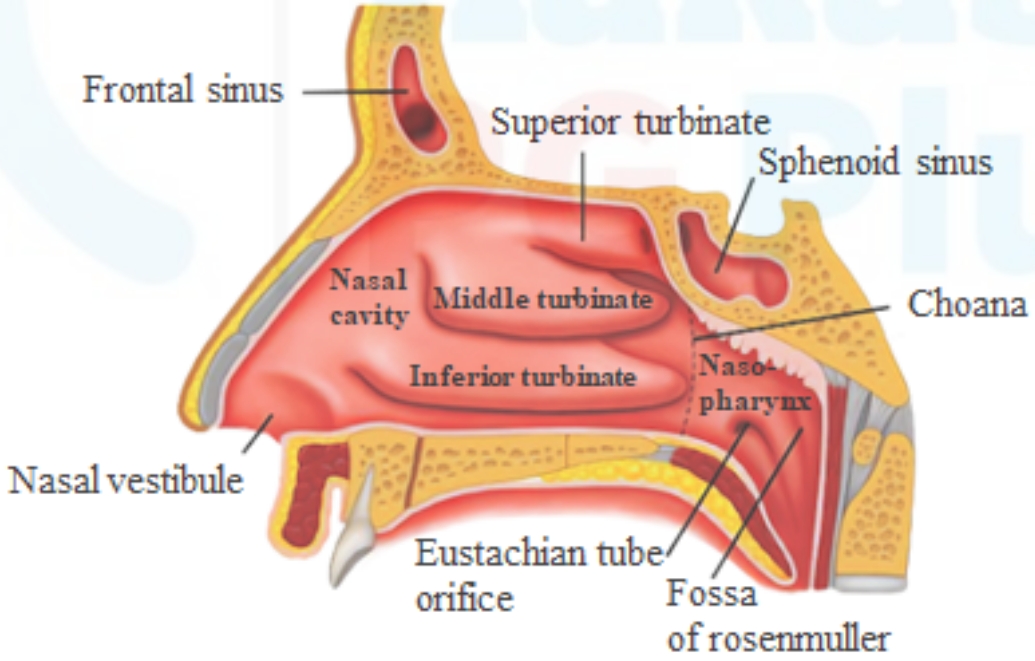

Lateral wall of the Nose

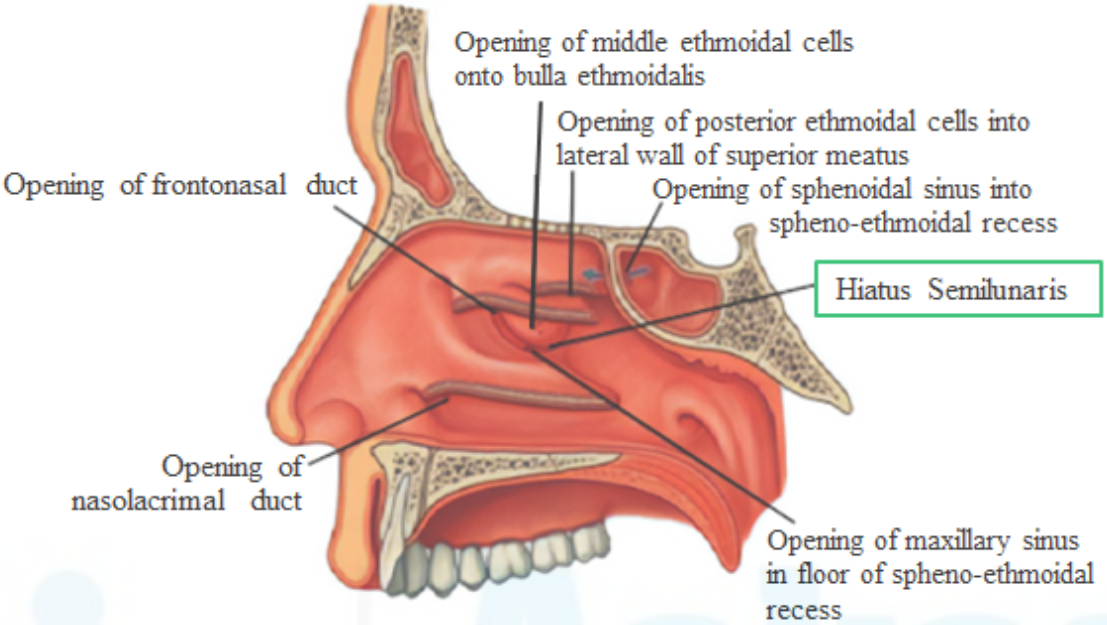

Lateral wall of the Nose

3.Answer: (C) Battle sign

Explanation: Battle sign is ecchymosis over the mastoid seen in fractures of temporal bone as shown in the given below image:

Battle sign

- Bezold's abscess: It is an abscess under the mastoid and/or in the digastric triangle when empyema of the mastoid bursts through the medial side of its tip as shown in the below given image:

Bezold's abscess

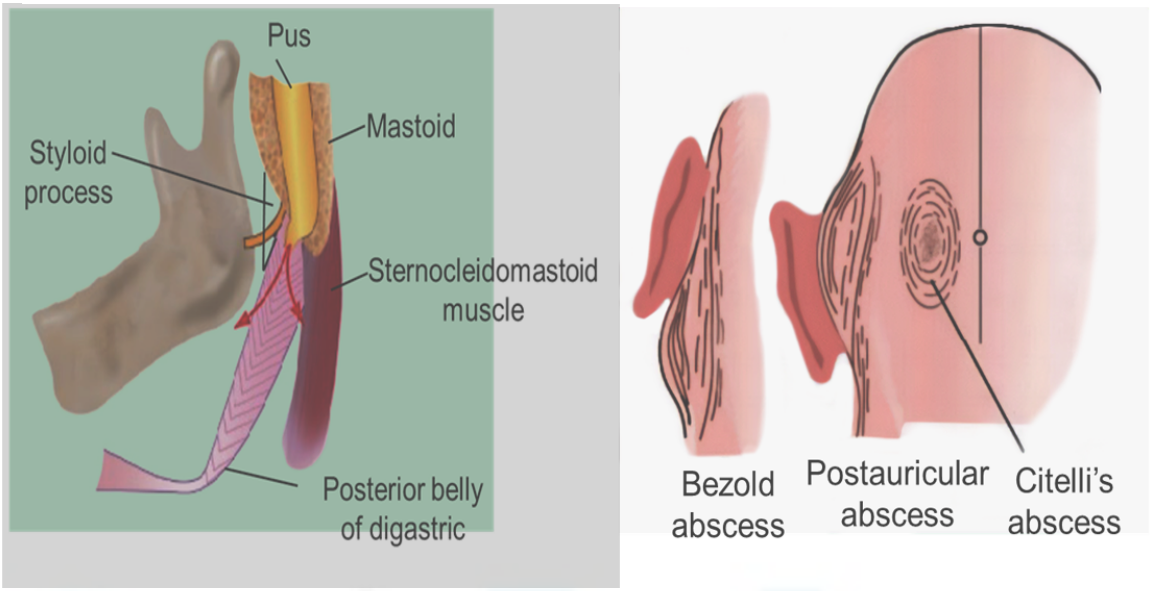

- **Delta Sign:** Delta sign is a CT sign of Dural venous sinus thrombosis, which occurs as a complication of Otitis Media where contrast outlines a triangular filling defect (marked by arrow in the below given image), which represents thrombus.

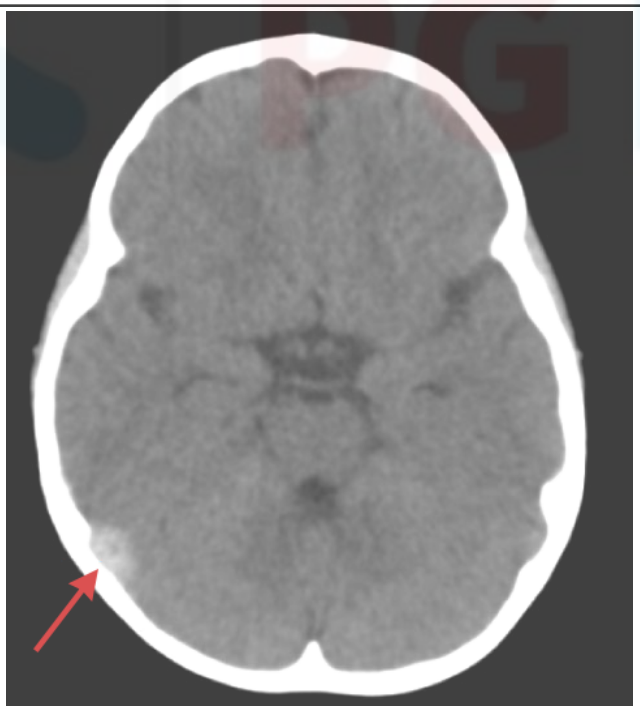

Delta Sign

- **Griesinger's sign:** Griesinger's sign is due to thrombosis of mastoid emissary vein impeding venous drainage resulting in oedema over the mastoid seen in Lateral Sinus Thrombosis.

4.Answer: B

Explanation: BERA, Otoacoustic Emissions(OAE) & Tympanometry are objective tests whereas Pure Tone Audiometry (PTA) is a subjective test where patient has to identify the sound & inform audiologist many times during procedure. So age, mental status, understanding commands are limiting factors unlike an Objective Hearing tests.

BERA	Noninvasive technique to find out the integrity of Auditory pathway Used to diagnose Retro-cochlear pathologies (Acoustic Neuromas) and Brainstem pathologies (multiple sclerosis and pontine tumors)
OAE	Tests the function of Cochlea Helps distinguish Cochlear from Retro-cochlear Hearing Loss OAE are absent in cochlear lesions but present in retro cochlear lesions

TYMPANOMETRY	It based on the principle that when sound strikes the Tympanic membrane, some of the sound energy is absorbed while rest is reflected. It helps find diseased or healthy status of Middle ear
PURE TONE AUDIOMETRY	It is a measure of threshold of hearing by air and bone conduction and thus degree and type of hearing

5.Answer: (B) Caldwell view

WATER'S VIEW (Occipito -mental view)	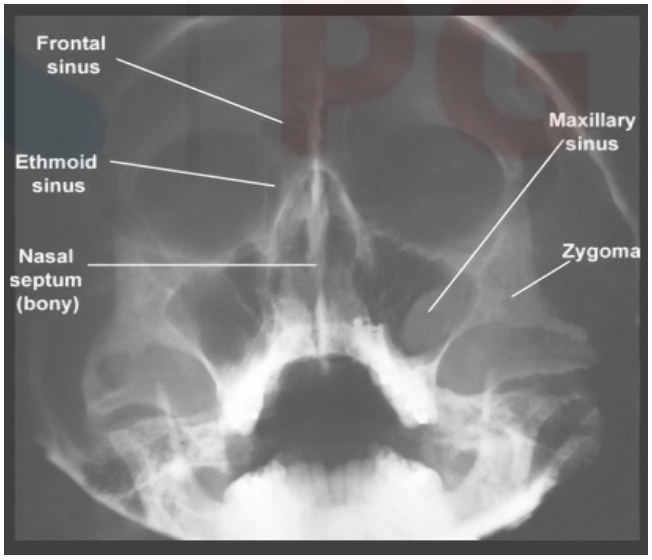	Nose and Chin of the patient touch the film while X ray beam is projected from behind. Commonest view taken to study the paranasal sinuses Structures seen:

	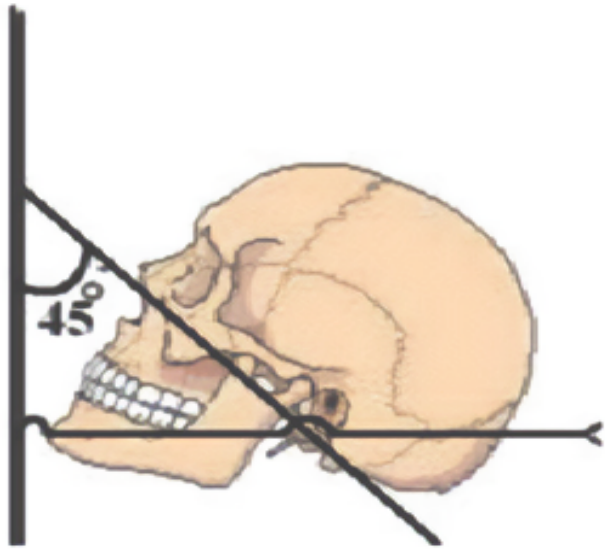	1) Maxillary sinus-seen **Best** 2) Frontal sinus 3) Sphenoid sinus(If the film is taken with open mouth)
CALDWELL VIEW (Occipito-frontal view)	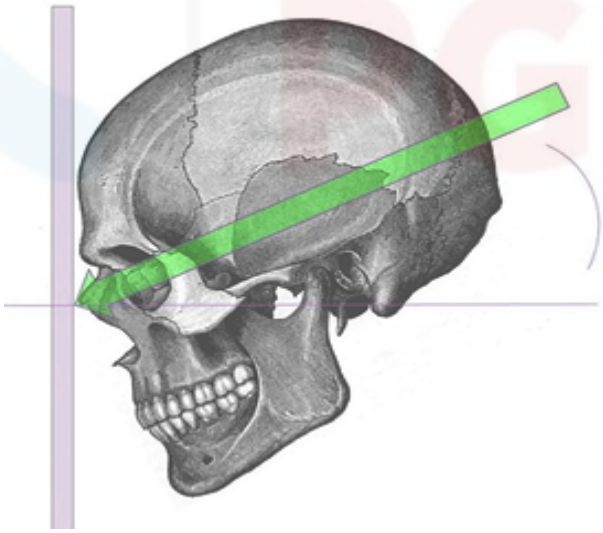	**1)** Frontal sinus-seen Best **2)** Ethmoid sinus **3)** Maxillary sinus

TOWNE's VIEW	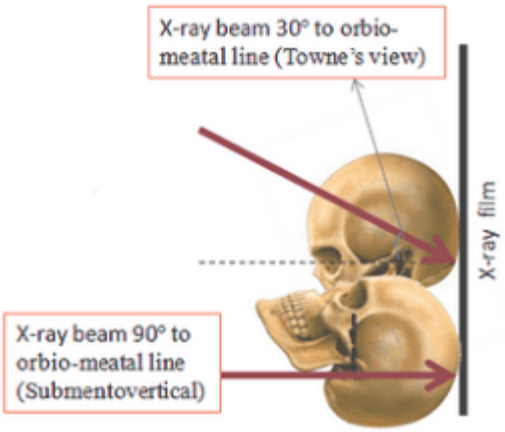	AP view with 30 degrees tilt from above and in front
LATERAL VIEW	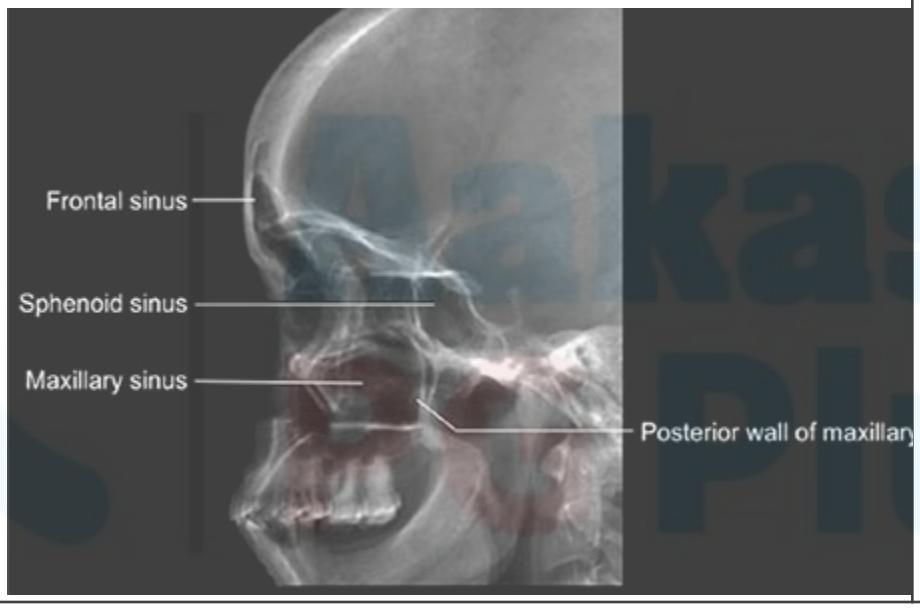	All sinuses visible on this view