



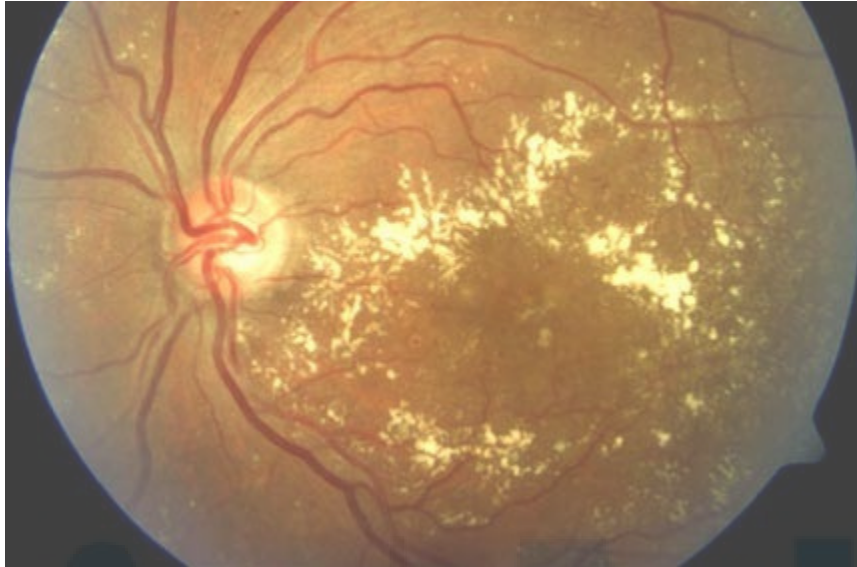
Aakash
PG Plus

OPHTHALMOLOGY

NEET PG 202

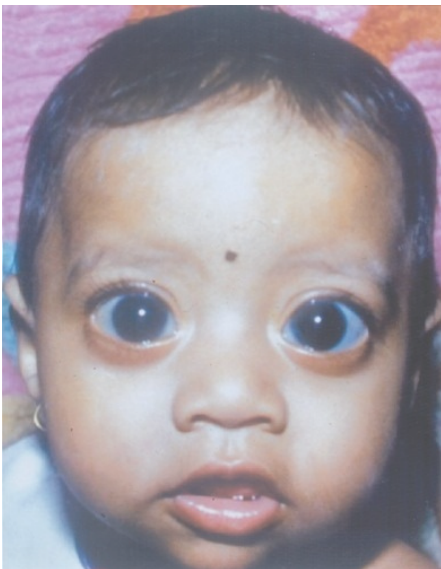RECALL QUESTIONS AND ANSWERS

1. A 60 year old male presented with painless loss of vision. Fundus examination is shown below. What is the likely finding and its cause?



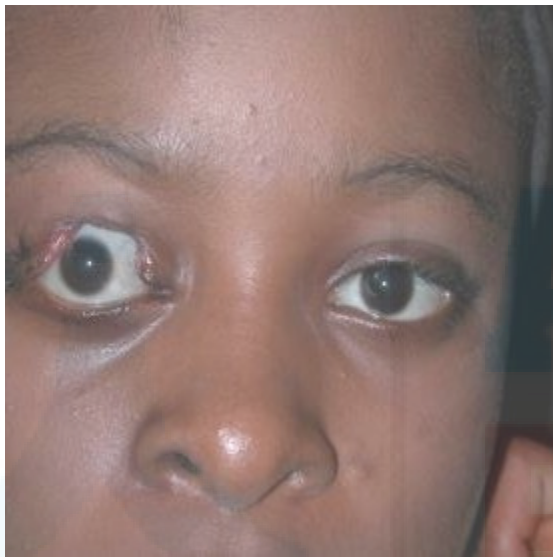
- A. Soft exudates, hypertension
- B. Hard exudates, diabetes mellitus
- C. Flame hemorrhages, hypertension
- D. Central retinal vein occlusion, diabetes mellitus

2. A 1 month old infant is brought to ophthalmology OPD with history of photophobia and lacrimation. Most likely diagnosis is



- A. Congenital glaucoma
- B. Birth trauma
- C. Ophthalmia neonatorum
- D. Mucopolysaccharidosis

3. A 15-year-old girl presented with the following disease. She is likely to suffer which of the following due to the deformity?



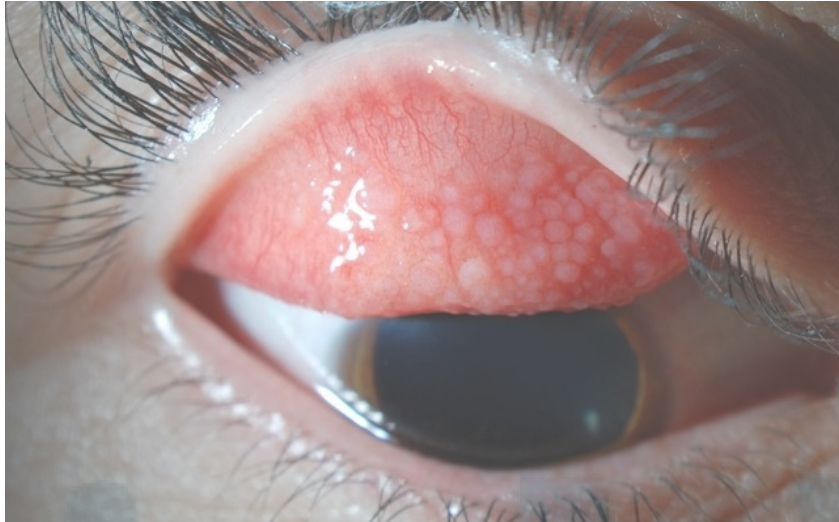
- A. Exposure keratitis
- B. Cataract
- C. Restricted ocular movements
- D. Amblyopia

4. An enucleation specimen from a child with white reflex and diminished on histology showed Flexner Wintersteiner rosettes and round cells. Most likely cause is?

- A. Retinoblastoma
- B. Medulloblastoma
- C. Rhabdomyosarcoma
- D. Lymphoma



5. A contact lens user presented with symptoms of watery discharge. Fluorescent staining was negative. Most likely diagnosis is



- A. Follicular conjunctivitis
- B. Giant papillary conjunctivitis
- C. Vernal catarrh
- D. Trachoma

6. A 15 year old girl with refractive error was not compliant with spectacles for her myopia. Which of the following is a suitable management option in her case?

- A. LASIK
- B. Femto LASIK
- C. Spherical equivalent spectacles
- D. ICL

7. In treatment of open angle glaucoma in a case of bronchial asthma, which of the following drugs is suitable?

- A. Alprostadil
- B. Gemeprost
- C. Carboprost
- D. Latanoprost



ANSWERS

1.B

2.A

3.A

4.A

5.B

6.D

7.D



Aakash
PG Plus

